



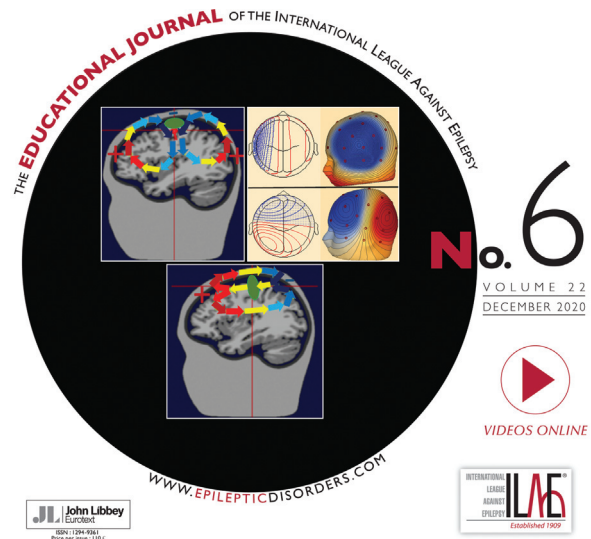
The key scientific and
medical informations

www.jle.com

Find the contents of this issue hereafter:

<http://www.john-libbey-eurotext.fr/fr/revues/medecine/epd/sommaire.md?type=text.html>

Epileptic Disorders



Arcueil, 12/30/2020

Angelo Russo

You will find below the electronic reprint of your article (pdf format):

Encephalopathy related to status epilepticus during sleep due to a *de novo* *KCNA1* variant in the Kv-specific Pro-Val-Pro motif: phenotypic description and remarkable electroclinical response to ACTH

published in:

Epileptic Disorders, 2020, Volume 22, Numéro 6

John Libbey Eurotext

This electronic reprint is provided for your exclusive use, and can't be communicated but for scientific and individual purposes. It mustn't, under any circumstances, be used or distributed for advertising, promotional or commercial purposes.

© John Libbey Eurotext, 2020

Encephalopathy related to status epilepticus during sleep due to a *de novo* *KCNA1* variant in the Kv-specific Pro-Val-Pro motif: phenotypic description and remarkable electroclinical response to ACTH

Angelo Russo¹, Giuseppe Gobbi², Antonella Pini¹, Rikke Steensbjerre Møller^{3,4}, Guido Rubboli^{3,5}

¹ IRCCS, Istituto delle Scienze Neurologiche di Bologna, UOC Neuropsichiatria Infantile, Bologna, Italia

² IRCCS, Istituto delle Scienze Neurologiche di Bologna, Bologna, Italia

³ Danish Epilepsy Center, Dianalund, Denmark

⁴ Syddansk Universitet, Odense, Denmark

⁵ University of Copenhagen, Copenhagen, Denmark

Received April 01, 2020; Accepted August 09, 2020

ABSTRACT – Although the classic phenotype of episodic ataxia type 1 (EA1) caused by variants in *KCNA1* includes episodic ataxia and myokymia, further genotype-phenotype correlations are difficult to establish due to highly heterogeneous clinical presentations associated with *KCNA1* pathogenic variants. *De novo* variants in the paralogous Pro-Val-Pro motif (PVP) of *KCNA2*, an essential region for channel gating, have been reported to be associated with severe epilepsy phenotypes, including developmental and epileptic encephalopathies (DEE). Here, we describe the first patient with a DEE who developed an encephalopathy related to status epilepticus during sleep (ESES) and cerebellar signs, harbouring a variant in the Kv-specific PVP motif of the *KCNA1* gene. Interestingly, he showed a remarkable long-term electroclinical response to IM ACTH therapy. This report extends the range of phenotypes associated with *KCNA1* variants to include that of ESES, and suggests that ACTH therapy is likely to have a positive effect in patients with these variants.

Key words: *KCNA1A*, developmental and epileptic encephalopathy, ESES, epilepsy, ACTH therapy

Correspondence:

Angelo Russo
Department of Pediatric Neurology,
IRCCS - Institute of Neurological Sciences
of Bologna,
via Altura 3, Bologna, Italy
<russo.neuroped@gmail.com>

Genetically determined defects in voltage-gated potassium channel function are responsible for a broad spectrum of epileptic conditions and paroxysmal neurological disorders (Browne *et al.*, 1994; Guerrini *et al.*, 2006). Pathogenic variants in *KCNA1*, encoding the voltage-gated potassium channel, Kv1.1, have been associated with episodic ataxia type 1 (EA1) characterized by episodic ataxia and myokymia (Browne *et al.*, 1994; Eunson *et al.*, 2000; Glaudemans *et al.*, 2009; Tomlinson *et al.*, 2010; D'Adamo *et al.*, 2014; Brownstein *et al.*, 2016). Furthermore, *KCNA1* variants have been associated with various forms of epilepsy, usually with a favourable seizure outcome (Zuberi *et al.*, 1999; Eunson *et al.*, 2000). Recently it has been shown that *KCNA1* pathogenic variants located in crucial regions for channel gating (p.Pro405Ser and p.Pro405Leu) can cause an infantile developmental and epileptic encephalopathy (DEE) (Rogers *et al.*, 2018), as reported also for *de novo* variants affecting the paralogous Pro-Val-Pro (PVP) motif of *KCNA2* (Pena *et al.*, 2015; Syrbe *et al.*, 2015; Masnada *et al.*, 2017). Interestingly, encephalopathy related to status epilepticus during slow sleep (ESES) associated with *KCNA1* pathogenic variants has never been observed, at variance with encephalopathies related to p.Pro405Leu *KCNA2* variants (Masnada *et al.*, 2017). ESES is characterized by a peculiar EEG pattern of extreme activation of epileptic activity during non-rapid eye movement (NREM) sleep (over 85% of NREM sleep, based on the original description by Patry *et al.* [1971]) and is associated with the appearance or worsening of cognitive impairment and/or behavioural disturbances (Filippini *et al.*, 2015; Tassinari *et al.*, 2019). Consensus on the therapy for ESES is lacking; in refractory cases, besides antiepileptic drugs, corticosteroids are an additional treatment option (Jensen *et al.*, 2019). Here, we describe a child with ataxia, epilepsy and learning disabilities who developed ESES and cerebellar signs, in whom genetic testing revealed a variant in the Kv-specific PVP motif of *KCNA1*. Interestingly, the patient showed a remarkable long-term electroclinical response, with ESES remission and improvement of cerebellar disorder and cognitive performances, to intramuscular (IM) ACTH therapy.

Case study

The patient was a nine-year, nine-month-old female who was born full-term via spontaneous vaginal delivery after an uncomplicated pregnancy. At two weeks of life, she presented with a sudden onset of multiple seizures per day characterized by generalized myoclonia, lasting less than one minute. EEG showed abundant and asynchronous epileptiform discharges on both hemispheres. Brain MRI was normal.

No dysmorphic features were present. Neurodevelopmental delay was noticed in the months following seizure onset. Seizures were never controlled by antiepileptic treatment, despite attempts with several antiepileptic drugs (AEDs), such as phenobarbital, carbamazepine, levetiracetam, phenytoin, lamotrigine, valproate and clobazam. At three years of age, focal seizures without awareness, triggered by fever and lasting longer than five minutes, appeared. The EEG continued to show very frequent bilateral asynchronous epileptiform discharges. At this age, she presented with intellectual disability (ID) with poor language skills, distal tremor of the upper limbs, and ataxia; autonomous walking was acquired at 30 months of age. Genetic testing including array CGH and Sanger sequencing of *SLC2A1*, *PCDH19*, and *SCN1A* was negative. At six years of age, next-generation sequencing (NGS) was performed using a panel targeting 95 genes associated with epilepsy. This study revealed a *de novo* heterozygous variant in *KCNA1* (NM_000217.2) c.1214C>T; p.Pro405Leu. The variant was confirmed by Sanger sequencing. Acetazolamide as add-on to valproic acid and lamotrigine was started with a transient (six-month) improvement of the seizure frequency and cerebellar signs. At seven years of age, the appearance of strikingly exaggerated spikes and waves during slow sleep (*figure 1*) associated with worsening of cognitive performances and cerebellar signs led to the diagnosis of ESES.

Negative myoclonus was infrequent and was not recorded during EEG polygraphy. Given its sporadic manifestation, it seemed unlikely that the ataxia depended on the negative myoclonus. IM synthetic ACTH at 0.025 mL/kg per day, utilizing a scalar dose protocol over 45 days, was administered. After the ACTH therapy, cognition and cerebellar signs improved, seizures disappeared, and the sleep EEG showed a striking reduction in epileptic activities which returned to baseline. EMG was normal. After one year of seizure freedom, brief seizures (less than one minute) relapsed with a frequency of 2-3 per year. At the last follow-up visit, two years after the ACTH therapy, the patient had a low seizure frequency with improvements on the EEG, however, cognitive performance and cerebellar signs following the ACTH treatment still persisted.

Discussion

Pathogenic variants in *KCNA1* are associated with a spectrum of phenotypes ranging from EA1 with or without myokymia, and various forms of epilepsy including DEE, to neuromyotonia and cerebellar dysfunction with or without cognitive/motor development delay (Browne *et al.*, 1994; Eunson *et al.*,

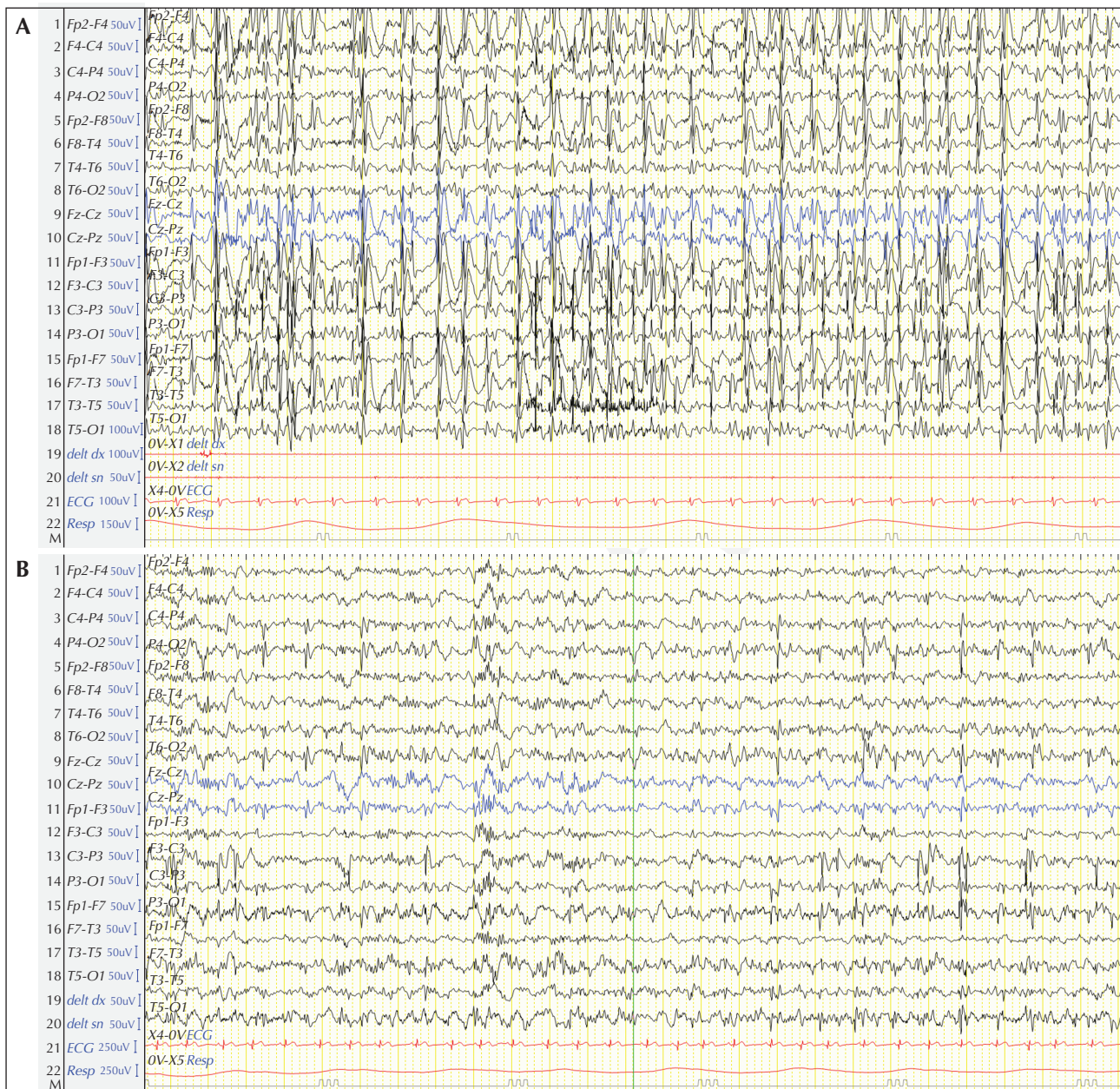


Figure 1. NREM Sleep EEG recording. (A) Pre-ACTH therapy: continuous spikes and waves during slow sleep. (B) Two years after ACTH therapy: independent epileptiform discharges over right parieto-occipital and left centro-temporal regions.

2000; Glaudemans *et al.*, 2009; Tomlinson *et al.*, 2010; D'Adamo *et al.*, 2014; Brownstein *et al.*, 2016). Several different disease-related *KCNA1* variants have been identified, and in most cases they demonstrated a dominant negative effect associated with remarkable phenotypic variability (Brownstein *et al.*, 2016; Tristan-Clavijo *et al.*, 2016), which may be due to genetic buffering and/or epigenetic or environmental factors. Our study describes a *de novo* heterozygous variant in *KCNA1* (NM_000217.2); c.1214C>T, p.Pro405Leu. This variant occurs in the highly conserved pore region of

the voltage-gated potassium channel Kv1.1. The variant is located in the S6 transmembrane domain and is predicted to be deleterious based on combined annotation dependent depletion (CADD) score and genomic evolutionary rate profiling (GERP). Recently it has been shown that gene variants located in an essential region for channel gating (p.Pro405Ser and p.Pro405Leu) can cause infantile DEE (Sheffer *et al.*, 1998; Eunson *et al.*, 2000; Parrini *et al.*, 2016; Rogers *et al.*, 2018), similar to what has been observed for *de novo* variants in the closely related potassium

channel *KCNA2* (Kv1.2) (Pena *et al.*, 2015; Syrbe *et al.*, 2015; Masnada *et al.*, 2017). In the present patient, the p.Pro405Leu *KCNA1* variant in the Kv-specific Pro-Val-Pro motif was associated with early-onset epilepsy; developmental, cognitive and motor delay; cerebellar signs; and, later on, during the disease course, worsening of the cerebellar disorder and cognitive performance and appearance of ESES, this latter finding has not previously been reported. Rogers *et al.* (2018) described a patient with the same variant and with an overlapping clinical picture during the first years of life (epilepsy onset during neonatal age, developmentally delayed with cerebellar signs, and good response to acetazolamide). After acetazolamide, a transient clinical improvement, lasting about six months, was reported, as shown in our case. The main difference is the appearance of ESES during follow-up in our patient, a feature previously not described.

The identified *KCNA1* variant has not been functionally characterized, however, recurrent *de novo* variants in the paralogous PVP motif of *KCNA2* have previously been shown to abolish channel function (Masnada *et al.*, 2017). We therefore speculate that loss-of-function of Kv1.1 could be related to the disease severity observed in our patient.

ACTH therapy is one of the first-line treatments for ESES (Jansen *et al.*, 2019), but no data exist on the effect of ACTH in patients with *KCNA1* variants. In our patient, the IM synthetic ACTH therapy was administered to treat ESES, which resulted in, besides ESES remission, improvement in cognition and seizures as well as a remarkable and unexpected long-term positive effect on cerebellar signs. In our patient, the improvement in cerebellar signs might have been dependent on remission of ESES, as motor disorders, including negative myoclonus, ataxia, and hemineglect, have been reported as clinical manifestations of ESES (Tassinari *et al.*, 2019). However, since the cerebellar signs remarkably improved, appearing less severe than before the appearance of ESES, we cannot exclude that ACTH treatment ameliorated the cerebellar functions independently of the improvement in ESES.

To our knowledge, this is the first report of a patient harbouring a *de novo* variant in the Kv-specific Pro-Val-Pro motif of *KCNA1* who developed ESES coupled with worsening of a cerebellar disorder, in whom IM ACTH therapy resulted in a long-term positive response. Although more cases are needed, we can speculate that *de novo* variants in the PVP motif of *KCNA1*, analogous to *KCNA2*, may be associated with severe early-onset DEE. Our case report expands the phenotypic spectrum of *KCNA1* variants and adds *KCNA1* to the list of genes that may be associated with an ESES phenotype (Lesca *et al.*, 2019). In addition, this case suggests that early and aggressive treatment with ACTH

should be considered in patients with a *de novo* variant in the PVP motif of *KCNA1*, not only to treat ESES but also to treat the cerebellar disorder. The hypothesis that *KCNA1* variants located within the Kv-specific PVP motif may confer electroclinical sensibility to ACTH therapy requires further investigation.

Conclusions

In conclusion, we describe a patient with DEE, harbouring a *de novo* variant in the Kv-specific PVP motif of the *KCNA1* gene, who developed cerebellar signs and an encephalopathy related to status epilepticus during sleep. This finding adds to the spectrum of phenotypes associated with *KCNA1* variants. Moreover, this patient demonstrated a remarkable long-term electroclinical response to IM ACTH therapy. □

Disclosures.

None of the authors have any conflict of interest to declare.

References

- Browne DL, Gancher ST, Nutt JG, *et al.* Episodic ataxia/myokymia syndrome is associated with point mutations in the human potassium channel gene. *KCNA1*. *Nature Genetics* 1994; 8(2): 136-40.
- Brownstein CA, Beggs AH, Rodan L, *et al.* Clinical heterogeneity associated with *KCNA1* mutations include cataplexy and nonataxic presentations. *Neurogenetics* 2016; 17: 11-6.
- D'Adamo MC, Gallenmuller C, Servettini I, *et al.* Novel phenotype associated with a mutation in the *KCNA1* (Kv1.1) gene. *Front Physiol* 2014; 5: 525.
- Eunson LH, Rea R, Zuberi SM, *et al.* Clinical, genetic, and expression studies of mutations in the potassium channel gene *KCNA1* reveal new phenotypic variability. *Ann Neurol* 2000; 48: 647-56.
- Filippini M, Boni A, Giannotta M, *et al.* Comparing cortical auditory processing in children with typical and atypical benign epilepsy with centrotemporal spikes: electrophysiologic evidence of the role of non-rapid eye movement sleep abnormalities. *Epilepsia* 2015; 56(5): 726-34.
- Glaudemans B, van der Wijst J, Scola RH, *et al.* A missense mutation in the Kv1.1 voltage-gated potassium channel-encoding gene *KCNA1* is linked to human autosomal dominant hypomagnesemia. *J Clin Invest* 2009; 119: 936-42.
- Guerrini R, Marini C. Genetic malformations of cortical development. *Exp Brain Res* 2006; 173(2): 322-33.
- Jansen FE, Nikanorova M, Peltola M. Current treatment options for encephalopathy related to status epilepticus during slow sleep. *Epileptic Disord* 2019; 21(1): 76-81.

Lesca G, Møller RS, Rudolf G, Hirsch E, Hjalgrim H, Szeppetowski P. Update on the genetics of the epilepsy-aphasia spectrum and role of *GRIN2A* mutations. *Epileptic Disord* 2019;21(1):41-7.

Masnada S, Hedrich UBS, Gardella E, et al. Clinical spectrum and genotype-phenotype associations of *KCNA2*-related encephalopathies. *Brain* 2017;140(9):2337-54.

Parrini E, Marini C, Mei D, et al. Diagnostic targeted resequencing in 349 patients with drug-resistant pediatric epilepsies identifies causative mutations in 30 different genes. *Hum Mutat* 2016;38(2):216-25.

Patry G, Lyagoubi S, Tassinari CA. Subclinical "electrical status epilepticus" induced by sleep in children. A clinical and electroencephalographic study of six cases. *Arch Neurol* 1971;24:242-52.

Pena S, Coimbra R. Ataxia and myoclonic epilepsy due to a heterozygous new mutation in *KCNA2*: proposal for a new channelopathy. *Clin Genet* 2015;87(2):1-3.

Rogers A, Golumbek P, Cellini E, et al. De novo *KCNA1* variants in the PVP motif cause infantile epileptic encephalopathy and cognitive impairment similar to recurrent *KCNA2* variants. *Am J Med Genet A* 2018;176(8):1748-52.

Scheffer H, Brunt ER, Mol GJ, et al. Three novel *KCNA1* mutations in episodic ataxia type I families. *Hum Genet* 1998;102(4):464-6.

Syrbe S, Hedrich UBS, Riesch E, et al. De novo loss- or gain-of-function mutations in *KCNA2* cause epileptic encephalopathy. *Nat Genet* 2015;47(4):393-9.

Tassinari CA, Cantalupo G, Dalla Bernardina B, et al. Encephalopathy related to status epilepticus during slow sleep (ESES) including Landau-Kleffner syndrome. In: Bureau M, Genton P, Dravet C, et al. *Epileptic Syndromes in Infancy, Childhood and Adolescence*. 6th Ed. Montrouge: John Libbey Eurotext Ltd, 2019: 261-83.

Tomlinson SE, Tan SV, Kullmann DM, et al. Nerve excitability studies characterize Kv1.1 fast potassium channel dysfunction in patients with episodic ataxia type 1. *Brain* 2010;133:3530-40.

Tristan-Clavijo E, Scholl FG, Macaya A, et al. Dominant-negative mutation p.Arg324Thr in *KCNA1* impairs Kv1.1 channel function in episodic ataxia. *Mov Disord* 2016;31:1743-8.

Zuberi SM. A novel mutation in the human voltage-gated potassium channel gene (*Kv1.1*) associates with episodic ataxia type 1 and sometimes with partial epilepsy. *Brain* 1999;122(5):817-25.

TEST YOURSELF



- (1) What are the possible factors determining the remarkable phenotypic variability associated with *KCNA1* pathogenic variants?
- (2) What was the main factor associated with improvement in cerebellar signs in our patient?

Note: Reading the manuscript provides an answer to all questions. Correct answers may be accessed on the website, www.epilepticdisorders.com, under the section "The EpiCentre".